

CHRONIC TRAUMA CASE WITH SEVERE INFECTION ON THE LEG

By Dr. Anirudh Mene

Place: Bhilai, India

Study Initiated on: 05/2013

Age of Patient: 45 yrs

Sex: Male

Type of Wound: Trauma Injury due to Road Accident

Age of Wound: 1 week

Wound Condition before SilverStream:

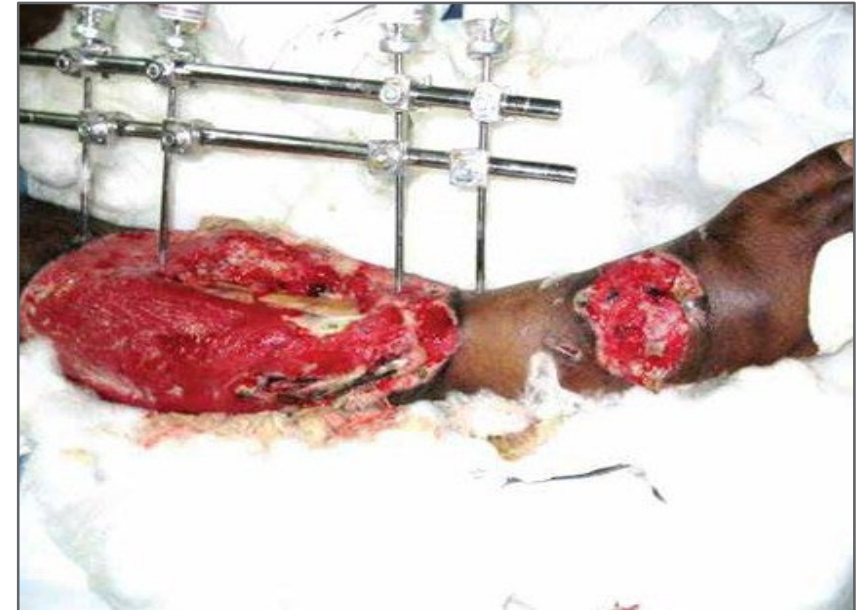Road accident case with **multiple open fractures** was put on external fixtures. The **wound developed infection** and the **bone was exposed with poor prognosis** and **no visible signs of healing**.

Previous treatment used:

Treated with NPWT, but due to external fixtures, **closure could not be achieved**.

In addition, due to **heavy infection**, **no visible effect of NPWT** seen.

BEFORE SILVERSTREAM - WEEK 0



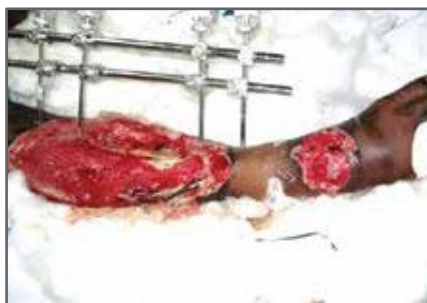CHRONIC TRAUMA CASE WITH SEVERE INFECTION ON THE LEG

SilverStream Treatment :

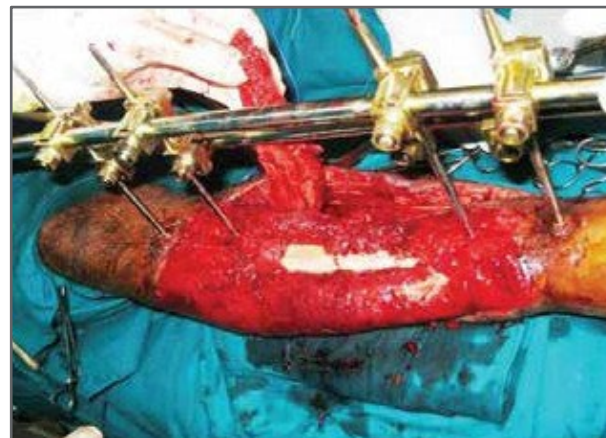
~ 50 ml of SilverStream was used daily for 2 weeks. Substantial wound healing enabled skin grafting to be performed after 2 weeks.

No. of 250 ml Silver Stream Bottles Used: 3

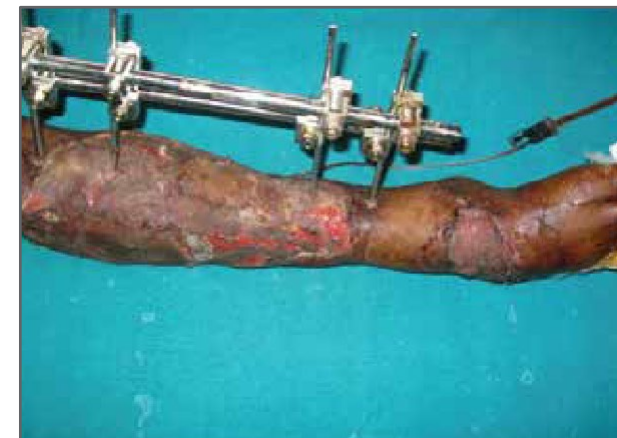BEFORE SILVERSTREAM
WEEK 0



AFTER SILVERSTREAM –
WEEK 1



AFTER SILVERSTREAM –
WEEK 2



Doctor Speaks:

”

*Very effective against infections.
helped wounds heal faster and facilitated
greater acceptance of Skin Grafts.*

Wound Characteristics	Week 0	Week 2
Wound Size	75% of left leg exposed & wounded	Skin grafting done
Signs of Infection	Yes	No
Granulation Tissue	Yes, 10%	Yes, skin grafting done.
Non-viable Tissue	Yes, 90%	No. 0%